


Volume 47, Number 2, June 2014

ISSN 1978-3728

Dental Journal

Published quarterly per year

Majalah Kedokteran Gigi



• Characteristic evaluation of rice husk ash with chitosan high molecule nanoparticle as dentinogenesis material • The relationship determination between menarche and the peak of skeletal maturation using hand wrist and cervical vertebrae index • Application of social learning theory in the management of children dental fear and anxiety

Dental Journal

Majalah Kedokteran Gigi

EDITORIAL BOARD OF DENTAL JOURNAL (MAJALAH KEDOKTERAN GIGI)

SK: 059/UN3.1.2/2014

January 2nd– December 31st, 2014

Patron:

Dean of Faculty of Dental Medicine Universitas Airlangga

Advisors:

Vice Dean I, Vice Dean II, Vice Dean III

Chief Editor:

Udijanto Tedjosongko, drg., Ph.D., Sp.KGA(K)
(Pediatric Dental Medicine – Universitas Airlangga)

Editorial Boards:

Prof. R.M. Coen Pramono D, drg., SU., Sp., BM(K) (Oral and Maxillofacial Surgery – Universitas Airlangga); **Prof. Dr. M. Rubianto, drg., MS., Sp.Perio(K)** (Periodontic – Universitas Airlangga); **Prof. Nairn Hutchinson Fulton Wilson, MSc., Ph.D., FDS** (Conservative Dentistry – University of Guy's Dental School, London); **Prof. W.J. Spitzer, DMD., MD** (Head Department of Cranio & Oral Maxillofacial Surgery Hamburg University, Germany); **Prof. Edward C. Combe, MSc., Ph.D., DDS** (Biomaterial – Minnesota University, U.S.A.); **Prof. Madya. H. AB. Rani Samsudin, DDS., FDSRC, AM** (Oral and Maxillofacial Surgery – University Sains, Malaysia); **Prof. Widowati Witjaksana, DDS., Ph.D** (Kulliyah of Dentistry, International Islamic University Malaysia); **Prof. Taizo Hamada, DDS., Ph.D** (Prosthodontic – Tohoku University, Japan); **Prof. Yukio Kato, DDS., Ph.D.** (Oral Bio Chemistry – University of Hiroshima, Japan); **Prof. Kozai Katsuyuki, DDS., Ph.D** (Pediatric Dentistry – University of Hiroshima, Japan); **Prof. dr. A.G.M. Tielens** (Medical Microbiology – University and Infections Diseases – Erasmus University Medical Centre, Rotterdam, The Netherlands); **Prof. Lakshman Samaranyake** (Oral Microbiology – The University of Hongkong); **Kok Van Kesel** (Medical Microbiology – University and Infections Diseases – Erasmus University Medical Centre, Rotterdam, The Netherlands); **Dr. Leslie Ang** (Restorative Dentistry – National Dental Centre of Singapore); **Prof. Dr. M. Suharsini, drg., MS., Sp.KGA** (Pediatric Dentistry – Universitas Indonesia); **Achmad Gunadi, drg., MS., Ph.D** (Prosthodontic – Universitas Negeri Jember)

Managing Editors:

Prof. Dr. Arifzan Razak, drg., MSc., Sp.Pro (Prosthodontics – Universitas Airlangga); **Prof. Dr. Latief Mooduto, drg., M.S., Sp.KG(K)** (Conservative Dentistry – Universitas Airlangga); **Prof. Dr. Mieke Sylvia M.A.R., drg., MS., Sp.Ort(K)** (Orthodontic – Universitas Airlangga); **Prof. Dr. Istiati Soehardjo, drg., MS** (Oral Biology – Universitas Airlangga); **Prof. Dr. Anita Yulianti, drg., M.Kes** (Dental Material – Universitas Airlangga); **Prof. Seno Pradopo, drg., SU., Ph.D., Sp.KGA** (Pediatric Dentistry – Universitas Airlangga); **Prof. Dr. Diah Savitri Ernawati, drg., M.Si., Sp.PM(K)** (Oral Medicine – Universitas Airlangga); **Prof. Thalca I. Agusni, drg., MHPEd., Ph.D., Sp.Ort(K)** (Orthodontic – Universitas Airlangga); **Dr. R. Darmawan Setijanto, drg., M.Kes** (Dental Public Health – Universitas Airlangga); **Dr. Elly Munadzirah, drg., MS** (Dental Material – Universitas Airlangga); **Priyawan Rachmadi, drg., Ph.D** (Dental Material – Universitas Airlangga); **Dr. Retno Pudji Rahayu, drg., M.Kes** (Oral Biology – Universitas Airlangga); **Dr. Eha Renwi Astuti, drg., M.Kes** (Dental Radiology – Universitas Airlangga); **Bagus Soebadi, drg., MHPEd., Sp.PM** (Oral Medicine – Universitas Airlangga); **Endang Pudjirachani, drg., MS., Sp.Pro** (Prosthodontic – Universitas Airlangga); **Markus Budi Rahardjo, drg., M.Kes** (Oral Biology – Universitas Airlangga); **Dr. Susy Kristiani, drg., M.Kes** (Oral Biology – Universitas Airlangga); **Dr. Ira Widjiastuti, drg., M.Kes., Sp.KG** (Conservative Dentistry – Universitas Airlangga); **Ketut Suardita, drg., Ph.D., Sp.KG.** (Conservative Dentistry – Universitas Airlangga); **Sianiwati Goenharto, drg., MS** (Orthodontic – Universitas Airlangga); **Devi Rianti, drg., M.Kes** (Dental Material – Universitas Airlangga); **Dr. Chiquita Prahasanti, drg., Sp.Perio(K)** (Periodontic – Universitas Airlangga); **Rostiny, drg., M.Kes., Sp.Pro** (Prosthodontic – Universitas Airlangga); **An'nissa Chusida, drg., M.Kes** (Oral Biology – Universitas Airlangga); **Eric Priyo Prasetyo, drg., Sp.KG** (Conservative Dentistry – Universitas Airlangga); **Els Sunarsih Budipramana, drg., MS., Sp.KGA(K)** (Pediatric Dentistry – Universitas Airlangga); **Dr. Hendrik Setiabudi, drg., M.Kes** (Oral Biology – Universitas Airlangga); **Otty Ratna Wahyuni, drg., M.Kes** (Dental Radiology – Universitas Airlangga); **Anis Irmawati, drg., M.Kes** (Oral Biology – Universitas Airlangga); **Yulianti, drg., M.Kes** (Oral Biology – Universitas Airlangga); **Retno Palupi, drg., M.Kes** (Dental Public Health – Universitas Airlangga); **Eka Agustina, drg., Sp.Perio** (Periodontic – Universitas Airlangga); **Febriastuti, drg., Sp.KG** (Conservative Dentistry – Universitas Airlangga); **Mega M. Puteri, drg., Sp.KGA** (Pediatric Dentistry – Universitas Airlangga)

Administrative Assistant:

Novi Dian Prastiwi (Faculty of Dental Medicine – Universitas Airlangga)

Thanks to editor in duty of Dental Journal (Majalah Kedokteran Gigi) Volume 47, Number 2, June 2014:

Prof. Dr. Hj. Roosje Rosita Owen, drg., Sp.KGA (Pediatric Dentistry – Universitas Padjadjaran)
Prof. Dr. Al Supartinah, drg., SU., Sp.KGA (Pediatric Dentistry – Universitas Gadjah Mada)
Prof. Dr. drg. Regina Titi Christinawati, M.Sc (Oral Biology – Universitas Gadjah Mada)
Maretaningtias Dwi Ariani, drg., M.Kes., Ph.D (Prosthodontics – Universitas Airlangga)

Editorial Address c/o:

Fakultas Kedokteran Gigi Universitas Airlangga
Jln. Mayjen. Prof. Dr. Moestopo No. 47 Surabaya 60132, INDONESIA
Telp. (062-31) 5039478/5030255. Fax. (031) 5039478/5020256
E-mail: dental_journal@yahoo.com Website: www.journal.unair.ac.id

Accredited No. 56/DIKTI/Kep/2012

Cover photo purchased from: www.folia.com
Invoice number: 206708019-204225738

Dental Journal

Majalah Kedokteran Gigi

CONTENTS

	<i>Page</i>
1. Evaluasi karakteristik abu sekam padi dengan kitosan molekul tinggi nanopartikel sebagai bahan dentinogenesis (<i>Characteristic evaluation of rice husk ash with chitosan high molecule nanoparticle as dentinogenesis material</i>) Pretty Farida Sinta Silalahi, Trimurni Abidin dan Harry Agusnar	63-66
2. The relationship determination between menarche and the peak of skeletal maturation using hand wrist and cervical vertebrae index Endah Mardiaty, Soemantry ES, Haroen ER, Thahar B and Sutrisna B	67-71
3. Maturasi dan erupsi gigi permanen pada anak periode gigi pergantian (<i>The maturation and eruption of permanent teeth in mixed dentition children</i>) Sri Kuswandari	72-76
4. Surgical exposure dan perawatan ortodontik pada impaksi gigi insisif sentral rahang atas (<i>Surgical exposure and orthodontic treatment on labially impacted maxillary central incisor</i>) Bingah Fitri Melati, Teguh Budi Wibowo, dan Betadion Rizki	77-81
5. Penurunan jumlah <i>Streptococcus mutans</i> pada saliva anak dengan ortodonti cekat setelah konsumsi yoghurt (<i>Reduction of salivary Mutans Streptococci in children with fixed orthodontic appliance after yoghurt consumption</i>) Dewi Anggreani Bibi, Udiyanto Tedjosasongko, dan Irmawati	82-86
6. Aplikasi teori belajar sosial dalam penatalaksanaan rasa takut dan cemas anak pada perawatan gigi (<i>Application of social learning theory in the management of children dental fear and anxiety</i>) Arlette Suzy Setiawan	87-91
7. Koreksi dimensi vertikal oklusal dengan modifikasi restorasi mahkota logam pada kasus severe-early-childhood-caries (<i>Correcting occlusal vertical dimension using modified stainless steel crown restoration in severe-early-childhood-caries case</i>) Amrita Widnyagarini dan Sarworini B Budiardjo	92-97
8. Koreksi gigitan terbalik posterior dan anterior dengan alat cekat <i>rapid maxillary expansion</i> dan elastik intermaksila (<i>Correction of posterior and anterior crossbite using fixed orthodontic appliance with rapid maxillary expansion and intermaxillary elastic</i>) Retno Dewati, Teguh Budi Wibowo, dan Masyithah	98-102

Research Report

The relationship determination between menarche and the peak of skeletal maturation using hand wrist and cervical vertebrae index

Endah Mardiaty,¹ Soemantry ES,¹ Haroen ER,² Thahar B¹ and Sutrisna B³

¹Departement Ortodontics, Faculty of Dentistry Universitas Padjadjaran, Bandung-Indonesia

²Departement Physiology, Faculty of Dentistry Universitas Padjadjaran, Bandung-Indonesia

³Faculty of Public Health, Universitas Indonesia, Jakarta-Indonesia

ABSTRACT

Background: Menarche and skeletal maturation indices are physiological maturation indicators that can be used to establish the maturation stage of individual patient in orthodontic treatment, especially in orthodontic growth modification and orthognatic surgery.

Purpose: The purpose of this study was to determine the relationship between menarche and the peak of skeletal maturation using hand-wrist and cervical vertebrae indexes. **Methods:** This was an observational diagnostic research with 220 female of Deutero-Malay Indonesian subjects aged 8-17 years from Dental Hospital Faculty of Dentistry Universitas Padjadjaran, and some privates orthodontic practice in Bandung. All subjects had hand-wrist radiograph and lateral cephalogram. Menarche data were collected through interview with the subjects and their parents. There were 89 subjects who already had menarche but only 84 of them remembered the month and year of their menarche. The stage of hand-wrist skeletal maturation was analyzed using Fishman method and cervical vertebrae maturation was analyzed using Baccetty et.al., method. **Results:** The result indicates that the menarche age of Indonesian Deutero-Malay subject were 12.47 ± 0.73 year. The youngest age of were 10.92 ± 0.0 year and the oldest were 13.83 ± 0.23 year. **Conclusion:** Menarche could be used as an indicator that the pubertal growth peak has been exceeded and to predict the end of the pubertal growth. This study showed that 0.49 years after MP3cap stage of hand-wrist skeletal maturation index and 0.69 years after CVMS2 stage of cervical vertebrae skeletal maturation index, the subject of Indonesian Deutero-Malay will have their menarche.

Key words: Menarche, hand-wrist maturation index, vertebrae maturation index, Indonesian Deutero-Malayid

ABSTRAK

Latar belakang: Menarke dan indeks maturasi skeletal merupakan indikator maturasi fisiologis yang dapat digunakan untuk menentukan tahap maturasi pasien pada perawatan ortodonti modifikasi pertumbuhan dan bedah ortognati. **Tujuan:** Tujuan penelitian ini adalah menentukan hubungan antara menarke dengan puncak pertumbuhan skeletal dengan menggunakan indikator maturasi hand-wrist dan vertebra servikal. **Metode:** Penelitian ini merupakan penelitian diagnostik obeservasional dengan 220 subjek perempuan umur 8-17 tahun yang datang ke Rumah Sakit Gigi dan Mulut Universitas Padjadjaran Bandung. Seluruh subjek penelitian mempunyai foto rontgen hand-wrist dan sefalogram lateral. Data menarke diperoleh melalui wawancara kepada pasien dan orang tuanya. Subjek yang telah mengalami menarke sebanyak 89 orang tetapi hanya 84 subjek yang ingat dengan tepat bulan dan tahunnya. Tahap maturasi hand-wrist dianalisis dengan menggunakan metode Fishman dan tahap maturasi vertebra servikal ditentukan dengan menggunakan metode Baccetty dkk. **Hasil:** Hasil penelitian menunjukkan bahwa rata-rata umur menarke terjadi pada umur $12.47 \pm 0,73$ tahun, dengan umur termuda pada $10,92 \pm 0,0$ tahun dan tertua pada umur $13,83 \pm 0,23$ tahun. **Simpulan:** Menarke dapat digunakan sebagai indikator untuk menentukan bahwa puncak pubertas telah terlampaui dan untuk memprediksi akhir pertumbuhan pubertal. Studi ini

menunjukkan bahwa 0,49 tahun setelah MP3cap stage dari maturasi skeletal pergelangan tangan dan 0,69 tahun setelah CVMS2 maturasi skeletal vertebra leher anak perempuan Indonesia deuteru melayu akan memasuki masa haid.

Kata kunci: Menarke, indeks maturasi hand-wrist, indeks maturasi vertebra servikal, subjek Indonesia ras Deuteru-Malayid

Correspondence: Endah Mardiaty, c/o: Fakultas Kedokteran Gigi, Universitas Padjadjaran. Jl. Sekeloa Selatan I No. 1 Bandung 40132, Indonesia. Email: endah_mardiaty@yahoo.com

INTRODUCTION

Growth and development is an important factor in the treatment of orthodontic growth modification and orthognathic surgery of skeletal class II and class III malocclusion. The ideal time for orthodontic growth modification treatment is during the active of pubertal growth, whereas ortognathic surgery is after the growth has been finished.¹⁻³ Active stage of pubertal growth, is more accurate if determined using physiological maturation indicators, such as hand-wrist or cervical vertebrae skeletal maturation index, dental maturation indicators and menarke as secondary sexual maturation indicator in female.⁴⁻⁶ In orthodontic treatment, cervical vertebrae maturation indicators can be observed directly on the lateral cephalogram that commonly used to determine the diagnosis of orthodontic treatment.⁶

Some studies showed that hand-wrist maturation index has polimorphism and sexual dimorfism^{7,8} whereas cervical vertebrae maturation index still controversi. Some studies indicates that cervical vertebrae maturation index is a valid and reliable method for determination the stages of pubertal growth while other studies is not valid.⁹⁻¹¹ Under these conditions menarke can be use as maturation index for determining the pubertal growth stages in female. Menarke is a physiological maturation indicator that easily identified through interview with patient or parents. Some studies showed that menarke reached approximately one year after the peak of skeletal growth.^{4,11} The purpose of this study was to determine the relationship between menarke and the peak of skeletal maturation using hand-wrist and cervical vertebrae indexes of Indonesian Deuteru-Malay subjects. In Indonesia, menarkeal data has been widely studied, but how it relates to the skeletal maturation is still unknown.

MATERIALS AND METHODS

This study was a diagnostic observational study. The subjects were 220 girls aged 8-17 years from orthodontic clinic Faculty of Dentistry, Universitas Padjadjaran, and some private specialist orthodontic practice in Bandung. Eighty nine subjects had menarke but only 85 subjects remember their menarke. The subjects of this study have hand-wrist radiograph and lateral cephalogram with inclusion criteria, such as: Indonesian Deuteru-Malay,

healthy, not suffering from serious diseases or systemic diseases, does not suffer from defects in dento-craniofacial structures, never have experienced with trauma in the neck and hand-wrist.

Hand-wrist maturation index of Fishman method and cervical vertebrae maturation index of Baccety *et al.*,⁵ method was used to analyzed the skeletal maturation stage, while menarke data was obtained retrospectively by interviewing the subject and parents. Subjects who did not remember their menarke were not included for analysis.¹²

Hand-wrist maturation indicators of Fishman method consists 11 skeletal maturation indicator (SMI), which is epiphysis width equal with diaphysis width (SMI1-SMI3), ossification of sesamoid bone (SMI4), capping of epiphysis to the diaphysis (SMI5-7) and fusion of epiphysis and diaphysis (SMI8-11) (Figure 1). Skeletal maturation indicator 1-4 shows the acceleration of pubertal growth, SMI 5-7 shows the peak of pubertal growth and SMI 8-11

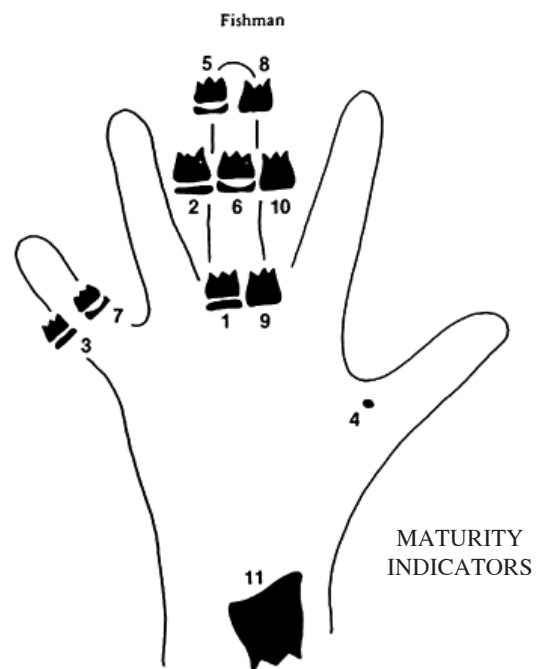


Figure 1. Location of assessment indicator hand-wrist maturation of Fishman method.¹³




Figure 2. Five-stages of cervical vertebrae maturation.⁵

Table 1. The age of hand-wrist maturation stages of pubertal growth (year)

Hand-wrists maturation stage										
PP3=	MP3=	MP5=	S	DP3 cap	MP3 cap	MP5 cap	DP3 u	PP3 u	MP4 u	Ru
9.41	9.72	10.40	10.84	11.24	11.82	12.87	13.01	13.68	14.66	15.93
±	±	±	±	±	±	±	±	±	±	±
0.14	0.66	0.74	0.69	0.58	0.56	0.55	0.78	0.83	0.89	0.63

shows a decrease and followed by the cessation of skeletal growth.¹² Cervical vertebrae maturation of Baccety method consists of 5 stages indicator, using the changes of the 3rd and 4th cervical vertebrae body that can be observed on lateral sefalogram (Figure 2).⁵

CVMS1 and CVMS2 showed pubertal growth acceleration, CVMS3, showed peak pubertal growth and CVMS 4-CVMS5 showed a decline and cessation of pubertal growth. To determine the validity and reliability of measurements, hand-wrist and lateral cephalogram from 10 subjects was randomly selected. Measurements were performed 3 times with two weeks of interval. There were no significant differences for the determination of the hand-wrist maturation stage ($p=0.042$) and for cervical vertebrae maturation stage ($p=0.375$).

Statistical analysis was performed using SPSS 17 to determine the mean and standard deviation of hand-wrist and cervical vertebrae maturation stages and the relationship with the menarche ($p=0.05$).

RESULTS

Menarche is an indicator of physiological maturation that can be used to determine the stages of pubertal maturation through interviews with patient or parents. Study showed that menarche occur one year after the peak of pubertal growth and indicate that skeletal growth has been decline and less effective for orthodontic growth modification treatment.⁶ The result of this study showed

Table 2. The age of cervical vertebrae maturation stages of pubertal growth (year)

CVMS1	CVMS2	CVMS3	CVMS4	CVMS5
9.91	10.61	12.58	13.88	15.14
±	±	±	±	±
0.89	0.98	1.28	1.40	1.15

Table 3. The mean age of menarche (year)

Calendar age	N	Average	SD	Minimum	Maximum
10 – 10.9	2	10.92	0.00	10.92	10.92
11 – 11.9	29	11.56	0.26	11.08	11.92
12 – 12.9	35	12.47	0.26	12.00	12.92
13 – 13.9	18	13.31	0.23	13.00	13.83
Total	84	12.300	0.73	10.92	13.83

that initial acceleration of pubertal growth, PP3= is reached at 9.41 ± 0.14 years. The peak of pubertal growth (MP3cap) indicator was reached at 11.82 ± 0.56 years (Tabel 1), the peak of pubertal growth of cervical vertebrae CVMS II is at 10.62 ± 0.98 years and CVMS III at 12.58 ± 1.2 years, while the average of menarche was 12.30 years (Table 2). One year after the peak of skeletal growth, female would have their menarche, and in this study, if menarche was associated with indicators of hand-wrist maturation and cervical vertebrae maturation indicator, showed that 0.47 years after MP3cap and 1.69 years after CVMS2 or 0.49 years before CVMS3, the subjects would have menarche.¹² The mean of menarche shown in Table 3.

DISCUSSION

Identification of pubertal growth stage, to determine how much the growth has been taken, or how long it will be finished, very important especially in orthodontic growth modification treatment and orthognatic surgery. Studies showed that the success of preventive and interseptive treatment in maxillo-mandibular disharmony, was in the begining until around the peak of pubertal growth, while orthogantic surgery was after pubertal growth has been completed.^{1,2}

The result of this study showed that using hand-wrist skeletal maturation index, initial acceleration stage of pubertal growth (PP3) is at 9.41 ± 0.14 years and the peak of pubertal growth (MP3cap) was reached at 11.82 ± 0.56 year (Table 1), while using cervical vertebrae maturation index the acceleration stage CVMS1 is at 9.91 ± 0.89 year, and the peak of pubertal growth (CVMS3) is 12.58 ± 1.28 year (Table 2). The average of menarche was 12.30 years (Table 3). If menarche was associated with skeletal maturation index showed that after 0.47 years of MP3cap stage and 1.69 years after CVMS2 or 0.49 years before CVMS3, the subjects would have menarche. The results of the study in Taiwan, from 148 subjects, showed that the average age of menarche is 11.97 years, and the average of menarche occurs at the stage IV-V NTUH-SMI and V, and between stages III and IV.¹³

The clinical implication in orthodontic treatment, patient who has menarche, has been in a decline stage of pubertal growth, and interceptive orthodontic treatment for maxillo-mandibular disharmony using functional appliances would have insignificant result. By knowing menarche of a patient, it can be used to predict how long the pubertal growth will be completed so that orthognatic surgery can be done without the risk of relaps due to the growth.

The result of this study indicate that the final stage of pubertal growth (Ru stage) using hand-wrist maturation indicator will be achieved in 3.63 years after menarche, while the final stage of cervical vertebrae maturation indicator (CVMS5) will achieved 2.84 years after menarche. Menarche data in this study was obtained retrospectively,

by interviews with subjects and their parents. Most subjects remember the exact month and year using indicators of special events like her birthday, school holiday, fasting month or new year eve.

Some menarche data in Indonesia, showed that rural children menarche ocured at 11.46 ± 0.99 years while urban children ocured at 11.87 ± 0.99 years.¹⁴ The research of Batubara¹⁵ in seven provinces in Indonesia, menarche ocured from the age of 12.5 years to 13.6 year. In this study the mean of menarcheal age was 12.30 ± 0.73 year with the youngest was 10.92 years and the oldest was 13.83 years. In industrial country the age menarche in USA shows at the age of 12.5 years. In European countries the average menarche in Turkish was estimated as 13.30 year, Swedia 13.05 ± 5 and UK 13.06 ± 0.10 years.¹⁶⁻¹⁸ For some countries in Asia, average menarche in Taiwan ocured at the age of 11.97 year, in Japan at the age of 12.2 year, and in Korea at the age of 13.10 ± 0.06 year. When the results of this study compared with several countries, the menarche of Indonesian children is later than the average Taiwanese children, or nearly the same as the Japanese children, but earlier than Korea, Turkey, Sweden, USA, UK and Canada.^{14,19-21} This differences can be caused by many factors such as the sample size, genetic, geographic, racial and ethnic.¹¹

The conclusion of this research is that menarche in Indonesia Deutero-Malay girls varies between the age of 10.92 ± 0.00 years to 13.31 ± 0.23 years with a mean of 12.30 ± 0.73 years. Menarche is associated with skeletal maturation stage hand-wrist and cervical vertebrae maturation stage, 0.47 years after MP3cap stage (11.83 years) and 1.69 years after CVMS2 or 0, 49 years before the stage CVMS3 (12.79 years) the subjects will have their menarche. Menarche can be used for determining the active growth stage of a girl and to predict the finished of pubertal growth.

REFERENCES

1. O'Brien K, Wright J, Conboy F, Appelbe P, Davies L, Connolly I, Mitchell L, Littlewood S, Mandall N, Lewis D, Sandler J, Hammond M, Chadwick S, O'Neill J, McDade C, Oskouei M, Thiruvengkatachari B, Read M, Robinson S, Birnie D, Murray A, Shaw I, Harradine N, Worthington H. Early Treatment for Class II division I malocclusion with the twin block appliance: a multi-center, randomized, controlled trial. *Am J Orthod Dentofacial Orthop* 2009; 135(5): 573-9.
2. Siara-Olds NJ, Pangrazio-Kulbersh V, Berger J, Bayirli B. Longterm dento skeletal changes with bionator, Herbs, Twin Block and MARA functional appliances. *Angle Orthod* 2010; 80(1): 18-29.
3. Faltin J, Faltin M, Bacetti T, Franchi L, Ghiozzi B, McNamara JJ. Long term effectiveness and treatment timing for bionator therapy. *Angle Orthod* 2003; 73(3): 221-30.
4. Fishman S. Maturational patterns and prediction during adolescence. *Angle Orthod* 1987; 57(3): 178-93.
5. Bacetti T, Franchi T, McNamara JJ. An improved version of the cervical vertebral maturation (CVM) method for assessment of mandibular growth. *Angle Orthod* 2002; 72(4): 316-23.
6. Demirjian A, Buschang R, Tanguay, Patterson K. Interrelationship among measures of somatic, skeletal, dental and seksual maturity. *Am J Orthod* 1985; 88(5): 433-8.

7. Flores-Mir C, Nebbe B, Major PW. Use of skeletal maturation based on hand-wrist radiographic analysis as a predictor of facial growth: a systematic review. *Angle Orthod* 2004;74: 118-124.
8. Santiago RC, Miranda LP, Vitral RWF, Fraga MR, Bolognese AM, Maia LC. Cervical vertebrae maturation as a biologic indicator of skeletal maturity. A systematic review. *Angle Orthod* 2012; 82(6): 1123-31.
9. Soegiharto B, Cunningham S, David R, Moles. Skeletal maturation in Indonesian and white children assessed with hand-wrist and cervical vertebrae methods. *Am J Orthod and Dentofacial Orthop* 2008; 134(2): 217-26.
10. Wong RWK, Alkhal HA, Rable BM. Use of cervical vertebrae maturation to determine skeletal age. *Am J Orthod Dentofacial Orthop* 2009; 136(4): 484.e1-6.
11. Gabriel DB, Southard K, Qian F, Marshal SD, Franciscus RG, Southard T. Cervical vertebrae maturation method: Poor reproducibility. *Am J Orthod Dentofacial Orthop* 2009; 136(4): 478e1-478 e7.
12. Fishman S. Radiographic evaluation of skeletal maturation. *Angle Orthod* 1982; 52(2): 88-112.
13. Lai EH, Chang JZ, Jane YCC, Tsai SJ, Liu JP, Chen YJ. Relationship between age at menarche and skeletal maturation stages in Taiwanese female orthodontic patients. *J Formos Med Assoc* 2008; 107(7): 527-32.
14. Darmawati D. Perbandingan usia menarke daerah pedesaan dan perkotaan di Tangerang. Dissertasi. Yogyakarta: Universitas Gadjah Mada; 2011.
15. Batubara JRL. Adolescent development. *Sari Pediarti* 2010; 12: 21-9.
16. Anderson SE, Dallal GE, Must A. Relative weight and race influence average age at menarche: results from two nationally representative surveys of US girls studied 25 years apart. *Pediatrics* 2003; 111(4 Pt 1): 844-50.
17. Tuğba A, İsmet K. Menarcheal age in Turkey: secular trend and socio-demographic correlates. *Annals of Human Biology* 2011; 38(3): 345-53.
18. Lindgren G. Height, weight and menarche in Swedish urban school children in relation to socio-economic and regional factors. *Ann Hum Biol* 1976; 3(6): 501-28.
19. Hosokawa M, Imazeki S, Mizunuma H, Kubota T, Hayashi K. Secular trends in age at menarche and time to establish regular menstrual cycling in Japanese women born between 1930 and 1985. *BMC Womens Health* 2012; 12: 19
20. Cho GJ, Park HT, Shin JH, Hur JY, Kim YT, Kim SH, Lee KW, Kim T. Age at menarche in a Korean population: secular trends and influencing factors. *Eur J Pediatr* 2010; 169(1): 89-94.
21. Mardiati E, Soemantri ES, Haroen ER, Thahar B, Sutisna B. Umur vertebra servikal dan tahap maturasi fisiologis untuk prediksi pertumbuhan pubertal anak indonesia ras Deutero-Malayu. Dissertasi. Yogyakarta: Universitas Padjadjaran 2010.