

Case Report

Noma management in a child with systemic lupus erythematosus

Irna Sufiawati¹, Asri Arum Sari², Budi Setiabudiawan³, and Rahmat Gunadi⁴

¹ Department of Oral Medicine, Faculty of Dentistry, Padjadjaran University

² Department of Oral Surgery, Faculty of Dentistry, Padjadjaran University

³ Department of Pediatric, Faculty of Medicine, Padjadjaran University

⁴ Department of Allergy and Immunology, Faculty of Medicine, Padjadjaran University
Bandung - Indonesia

ABSTRACT

Background: Noma, also known as cancrum oris, is an orofacial gangrene, which during its fulminating stage causes progressive and mutilating destruction of the infected tissues. The disease occurs mainly in children with malnutrition, poor oral hygiene and debilitating concurrent illness. **Purpose:** The aim of this paper was to report a unique case of noma associated with systemic lupus erythematosus in an 8-year-old boy. **Case:** An 8-year-old boy referred to Oral Medicine Department complaining about an ulcer at the left corner of his mouth for 1 month, painful and difficulty in opening the mouth. The patient was diagnosed systemic lupus erythematosus since 14 months before and had been given immunosuppressive therapy. The patient was also diagnosed severe malnutrition. Haematologic investigations revealed anemia. **Case management:** Panoramic radiography was performed to check for dental or periodontal foci of infection, but no abnormalities were present. The microbiology examination revealed *Fusobacterium necrophorum*, *Staphylococcus aureus*, and *Klasiella*. The patient has been treated with oral irrigation using hydrogen peroxide, saline and 0.2% chlorhexidine, thus helped to slough the necrotic tissue. Oral antibiotics and analgesics were prescribed. The patient was admitted to hospital under the care of a pediatrician, allergy and immunology specialist, and a nutritionist. The result of the comprehensive disease management showed that the lesion healed completely, but leaving a scar on his corner of the mouth. Its physical effects are permanent and may require reconstructive surgery to be repaired by oral surgeon. **Conclusion:** Noma is not a primary disease, there are various predisposing factors usually precede its occurrence. The management of noma requires a multidisciplinary approach.

Key words: Noma, systemic lupus erythematosus, malnutrition, management

ABSTRAK

Latar Belakang: Noma, dikenal sebagai cancrum oris, adalah gangren pada daerah orofasial, yang menyebabkan kerusakan progresif dari jaringan yang terinfeksi. Penyakit ini terjadi terutama pada anak dengan gizi buruk, kesehatan mulut yang buruk dan penyakit yang melemahkan. **Tujuan:** Makalah ini bertujuan untuk melaporkan sebuah kasus noma yang unik pada seorang anak laki-laki berusia 8 tahun yang menderita lupus eritematosus sistemik. **Kasus:** Seorang anak laki-laki 8 tahun dirujuk ke Bagian Ilmu Penyakit Mulut, mengeluh adanya luka di sudut mulut sebelah kiri yang telah diderita selama 1 bulan, terasa sangat sakit dan sulit membuka mulut. Pasien didiagnosis lupus eritematosus sistemik sejak 14 bulan sebelumnya dan telah diberikan terapi immunosupresif. Pasien juga didiagnosis menderita malnutrisi yang berat. Pemeriksaan hematologi menunjukkan pasien menderita anemia. **Tatalaksana kasus:** Radiografi panoramik dilakukan untuk memeriksa fokus infeksi dental atau periodontal, tetapi tidak ditemukan adanya kelainan. Pada pemeriksaan mikrobiologi ditemukan adanya *Fusobacterium necrophorum*, *Staphylococcus aureus*, dan *Klasiella*. Perawatan pada pasien meliputi irigasi pada daerah gangren dengan hidrogen peroksida, larutan salin dan klorheksidin 0,2% untuk membersihkan jaringan nekrotik. Pasien juga diberikan antibiotik dan analgesik. Pasien dirawat di rumah sakit di bawah perawatan dokter spesialis anak, dokter spesialis alergi imunologi, dan ahli gizi. Hasil penatalaksanaan penyakit secara komprehensif memperlihatkan adanya penyembuhan, tetapi meninggalkan jaringan parut pada sudut mulutnya. Kelainan fisik tersebut bersifat permanen dan memerlukan pembedahan rekonstruktif oleh dokter gigi spesialis bedah mulut. **Kesimpulan:** Noma bukanlah penyakit primer, terdapat berbagai faktor predisposisi yang biasanya mendahului terjadinya penyakit tersebut. Pengelolaan noma memerlukan pendekatan multidisiplin.

Kata kunci: Noma, lupus eritematosus sistemik, malnutrisi, penatalaksanaan

Correspondence: Irna Sufiawati, c/o: Bagian Ilmu Penyakit Mulut, Fakultas Kedokteran Gigi Universitas Padjadjaran. Jl. Sekeloa Selatan I No. 1 Bandung 40132. E-mail: irnasufiawati@yahoo.com

INTRODUCTION

Noma, also known as cancrum oris, is a destructive gangrenous stomatitis of the mouth, soft and hard tissues of the face.¹ It may lead to devastating facial deformity, circumferential scarring, stenosis of the mouth, and in many cases death.² "Noma" derives from the Greek word *nemo*, meaning "to graze" or "to devour".³ The disease typically affects mostly children between 2 to 16 years of age.¹ The epidemiology of noma has not changed much over the years, except that there has been a reduction in the mortality rate from 90% to about 8% to 10%, mainly because of modern antibiotics.^{3,4} The WHO estimated that 500,000 people are affected with 100,000 new cases each year. Noma has disappeared from the industrialized countries since the 20th century, but is common in the third world especially in Africa.⁵ This disease occurs almost exclusively among poor malnutrition children in developing countries.^{6,7}

The exact cause of the disease is still not known.¹ It is postulated that the disease is triggered by a consortium of micro organisms of which *Fusobacterium necrophorum* is a key component.^{2,8} Symbiotic relationship between fusiform bacilli and non-hemolytic streptococci and staphylococci has been considered a significant factor in the development of noma. Anaerobic bacteria may be present in rapidly progressing disease.⁹⁻¹¹ Noma is considered to represent the "face of poverty" because factors connected with poverty, such as chronic malnutrition, poor oral hygiene, poor environmental sanitation, exposure to animal and human fecal material, and exposure to viral and bacterial infections, contribute to disease progression.^{3,12,13} Weak immune system, past history of measles, scarlet fever, typhoid, bacillary dysentery, malaria, whooping cough, tuberculosis, malignancy and HIV are also predisposing factors of noma.^{3,13,14}

This case report describes the risk factors and management of noma in 8-year-old boy suffering from systemic lupus erythematosus (SLE). It is expected that this report will provide information for the clinician that a team approach is needed in better managing this devastating disease.

CASE

On 19th December 2008, an 8-year-old boy with systemic lupus erythematosus (SLE) who was under treatment at Department of Pediatric Hasan Sadikin Hospital was referred to Department of Oral Medicine for evaluation and management for his oral disease. Systemic lupus erythematosus is a multisystem autoimmune disease characterized by general autoantibody production and a wide range of mucocutaneous, renal, neuropsychiatric, cardiovascular, infectious, and hematologic manifestations. His mother reported that there was an ulcer at the left side of lips 1 month earlier. There was no history of trauma. She also reported discharge of pus from the left corner of

his mouth and difficulty in opening the mouth. The patient felt painful while he was eating. He had intermittent fever for the last one month. For the next 4 months, the patient kept complaining about his stomachache. He just ate 3 spoons of food daily, drank 5 glasses of milk, and seldom ate at night.

The patient has been suffering from SLE since 14 months ago before being admitted to the hospital and he was treated out of the hospital at Department of Allergy and Immunology Hasan Sadikin Hospital regularly. The result of systemic lupus erythematosus activity index (SLEDAI) examination showed number 12 meaning that he was in moderate of SLE disease activity. Hematologic investigations showed anemia (Haemoglobin 9.3 g/dl, Hematocrit 28 %). The patient was diagnosed moderate malnutrition. The patient had also aphthous stomatitis and oral candidiasis histories. Some medicines that he consumed were prednisone 3 × 2.5 mg daily, Rocatrol caps 1 × 0.25 mcg daily, Ca carbonate 3 × 250 mg daily, Ranitidine tablet 150 mg 2 × 1/3 tablet daily, supplements and 1300 kcal diet.

The patient appeared malnourished and weighed only 14 kg. His temperature was 38,5° C at the time, but all other vital signs were within normal limits. Extra oral examination revealed necrotizing tissue at the left corner of his mouth about 2 × 2 cm in size surrounded by oedematous tissue showing a mild to moderate erythema (Figure 1). The left submandibular lymph nodes was mildly painful, palpable, tender, and mobile. Submental, right mandibular, and cervical lymph nodes were unpalpable. Intraoral examination couldn't be applied because of restricted mouth opening. It was also not possible to obtain intraoral photographs.

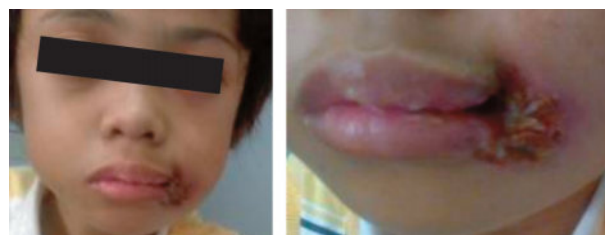

Figure 1. Day 1. Extraoral photographs showed the swelling and crust from the corner of the mouth.

CASE MANAGEMENT

The patient was referred to microbiology laboratory to identify the microorganism of the necrotizing tissue. Orthopantomogram (OPG) was performed to check for dental or periodontal foci of infection, but no abnormalities were evident. Based on the clinical and radiographic results, suspect of noma diagnosis was made. Therefore, the treatment on the first day was irrigation with hydrogen peroxide, saline, and 0.2% chlorhexidine. Furthermore, the patient was given oral antibiotics (amoxicillin 250 mg three times daily and metronidazole 200 mg three times daily) for

15 days, analgesics (paracetamol 500 mg $3 \times \frac{1}{2}$ tablet daily), 0.2% chlorhexidine gluconate gargles were prescribed. Oral hygiene instructions were also given to his mother.

On December, 30th, 2007 (11 days later), the patient came to the hospital for medical control. The pain of the mouth has decreased. There was no improvement healing of the noma. The necrotizing tissue on his mouth was enlarging. There was discharge of pus from the corner of the mouth (Figure 2). The result of culture testing showed *Fusobacterium necrophorum*, *Staphylococcus aureus*, and *Klasiella*. At this time, a definitive diagnosis of noma was made. The patient did not consume the medicine regularly because he didn't feel convenient. The patient was referred again to microbiology laboratory for further examination (sensitivity test) because the previous treatment did not show recovery. Hydrogen peroxide, saline, and 0.2% chlorhexidine were applied again to the wound. The dressing was also done to remove sloughed tissue. The same oral antibiotics and nutritional supplements were still given. At that day, the patient was admitted to the hospital under paediatrician and allergy and immunology specialist for evaluation of SLE disease because his condition was decreasing. He was also referred to Department of Nutrition for malnutrition evaluation. Parenteral fluid supplement replacement was also provided to maintain electrolyte balance.

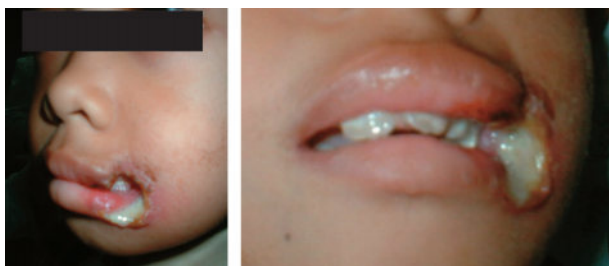

Figure 2. Day 7. Discharge of pus from the corner of the mouth.

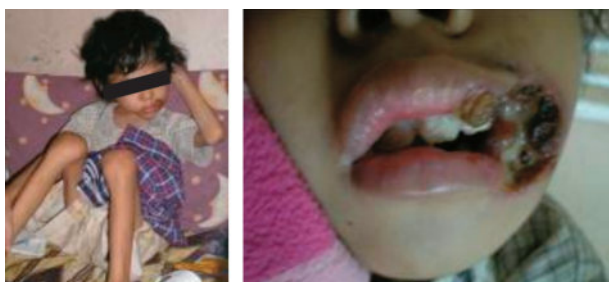


Figure 3. Day 16. (a) The patient was diagnosed marasmus (severe malnutrition). (b). Extensive necrosis affecting soft tissues.

On January, 5th, 2008 (16 days later), the necrotizing tissue at the corner of the mouth became larger (Figure 3). The patient was diagnosed marasmus (severe malnutrition) by his nutritionist. The result of sensitivity test showed that the patient has still sensitive to amoxicillin, but resistant to ampicillin, ceftazidime, chloramphenicol, ciprofloxacin,

erythromycin, and metronidazole, intermediate to oxacilline, ceftriaxone dan cotrimoxazole. After this testing available, high dose antibiotic therapy was instituted to halt the spread of noma. Parenteral antibiotics were started. The drug dosages were adjusted according to the patient's age to prevent toxic effects. In addition, adequate hydration, correction of electrolytes and vitamin deficiencies with provision of sufficient nutritional support were also given by nutritionist. Local debridement of necrotic tissue was still performed throughout the course of the treatment.

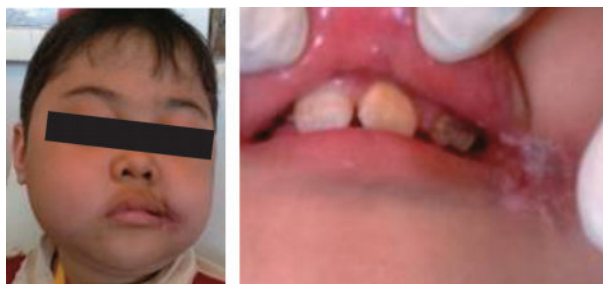

Figure 4. Day 60. (a) Moon face caused by corticosteroids therapy. (b) Healing lesion.

The lesion healed completely after 2 months, at the last visit on February 12th, 2008 (Figure 4). But there was leaved scar of his corner of the mouth. Moon face as a side-effect of corticosteroids was seen in this patient (Figure 4-a). The proposed treatment was polishing of all teeth and reconstructive surgery in the left corner of his mouth. The patient was then referred to Department of Oral Surgery to have reconstruction done. Until this report was made it has not been done yet because of his poor health condition.

DISCUSSION

In this case, the diagnosis of noma was made based on clinical features supported by microbiology examination. Initially, the patients had an ulcer on the left corner of his mouth and then necrotizing tissue and discharge of pus from the corner of the mouth appeared rapidly. Clinical feature of noma was began at the mucous membranes lining of cheeks which become inflamed and develop as an ulcer. The infection spreads from the mucous membranes to the skin thus causing necrosis of the tissues of lips and cheeks.¹⁵ Foul smelling, purulent oral discharge were associated with profuse salivation, anorexia and palpable cervical lymphadenopathy. Noma causes sudden, rapidly progressive tissue destruction.¹

Definitive diagnosis of noma with SLE was based on the result of culture testing which showed *Fusobacterium necrophorum* (*F. necrophorum*), *Staphylococcus aureus*, and *Klasiella*. It is difficult to pinpoint the specific trigger agent in the complex microbiota of a noma lesion. It has been speculated that *Borrelia vincentii* and *Fusobacterium* are prominent bacteria in such lesions.^{2,8} Recent reports suggest that besides fusiform bacilli and spirochetes,

other anaerobic bacteria are present in a relatively high proportion of noma lesions.⁸ *F. necrophorum* is considered a key component. This organism produces dermatotoxins, which could explain the rapid progression of the disease.⁹ *F. necrophorum* elaborates several dermonecrotic toxic metabolites and is acquired by the impoverished children via fecal contamination, resulting from shared residential facilities with animals and very poor environmental sanitation. Anaerobic bacteria may be present in rapidly progressing disease.^{9,10} *Prevotella intermedia* has the ability to break down lipid structures, which contributes to tissue destruction. It also produces proteolytic enzymes capable of breaking down immunoglobulin G, which impedes elimination of microorganisms.¹²

It was supposed that there were various factor stimulating susceptibility of the disease in the patient of this case. The patient was diagnosed severe malnutrition called marasmus (a condition primarily caused by a deficiency in calories and energy) by nutritionist. Malnutrition leads to alteration in cell-mediated immune function and early breakdown of the epithelial tissues, alterations in the oral mucosa facilitate invasion by pathogens.¹² Eating difficulties due to infection further was aggravated by any existing malnutrition. Therefore, malnutrition can be considered to have been a major predisposing factor for development of noma in this patient. There was a complex three-way relationship existed between malnutrition, immune dysfunctions in the host, and increased susceptibility to infections.⁹ Studies of the effect of malnutrition on oral microbial ecology in the village of Nigerian children have demonstrated prominently increased recovery of spirochetes and anaerobic rods compared to control groups of well-fed children from the same ethnic background.¹⁶ Cellular depletion of key nutrients such as zinc, retinol, ascorbic acid, and the essential amino acids, will impair the structural integrity of the oral mucosa, thus creating easy portals of entry for the pathogenic microorganisms and their products.¹⁷⁻¹⁹

Another predisposing factor that could lead noma in the patient was the use of long term corticosteroids for his systemic disease. Systemic lupus erythematosus (SLE) is an autoimmune disease characterized by typical involvement of many different organ systems and by immunological abnormalities, such as hyperactive B cells producing various autoantibodies.²⁰ The aetiology of SLE is unspecific. It is likely that a combination of genetic, environmental, and possibly hormonal factors worked together to cause the disease. This led to inflammation and damage to various body tissues.^{20,21} The diverse presentations of lupus range from rash and arthritis through anemia and thrombocytopenia to serositis, nephritis, seizures, and psychosis. SLE is considered a predominantly female disease. Lupus should be part of the differential diagnosis in virtually any patient presenting with one of these clinical problems, especially in female patients between 15 and 50 years of age.²² Approximately 20% of all patients who have SLE are diagnosed in childhood. The diagnosis of SLE often is considered in children who have prolonged unexplained

complaints.²³ The mainstay of lupus treatment involves the use of corticosteroid hormones, such as prednisone. They work by rapidly suppressing inflammation. Persons who have been on *long-term* oral corticosteroids may become immunosuppressed and *susceptible* to infection. Increased steroid levels in the mouth could also serve as a rich nutrient source for anaerobes.²⁴ Thus, the patient has high risk for developing secondary infection such as noma.

Lupus can affect many parts of the body, including the gastrointestinal (GI) disorders. William Osler, in 1895, was the first to emphasize that the GI manifestations may overshadow other aspects of the disease and mimic any type of abdominal condition. GI manifestations of SLE include mouth ulcers, dysphagia, anorexia, nausea, vomiting, haemorrhage and abdominal pain. Anorexia, nausea and vomiting are seen in up to 50% of patients with SLE. However, they may be due to the disease, represent intercurrent processes (e.g. secondary to uraemia) or side-effects of medication.²⁵ These complications may lead malnutrition in patient with SLE.

In the early stages, the child need oral irrigation with hydrogen peroxide, saline and 0.2% chlorhexidine, thus helps to slough the necrotic tissue. Amoxicillin and metronidazole were given to the patient. As there is no clear consensus but most authors recommend penicillin plus metronidazole to cover predominant organisms. Medication needs to be continued for at least 14 days. After the result of sensitivity testing, other antibiotics were given parenterally. The use of antibiotic may cause *Candida albicans* overgrowth, thus requires antifungal coverage with Nystatin.¹

After being treated together at the same time with the systemic disease, finally noma showed recovery. Usually in such cases, maxillofacial and plastic surgeons repair the defect once the infection subsides. Patients who have risk factors, such this child, have to be prevented from noma, by increasing the nutritional status of children and decreasing the animal-fecal contamination of the environment. Proper and early treatment of oral lesions, and also maintenance of oral health would seem to be the means of control for preventing noma.⁸

It was concluded that noma is not a primary disease, there are various predisposing factors usually precede its occurrence, such as severe malnutrition and immune system disease with intensive immunosuppressive therapy. This case report may guide the clinician in better managing this devastating disease. Management of noma requires a multidisciplinary team approach.

REFERENCES

1. Wazir SM, Khan su. Cancrum oris. *Journal of Pakistan Association of Dermatologists* 2008; 18: 110–2.
2. Falkler WA, Enwonwu CO, Idigbe EO. Isolation of *Fusobacterium necrophorum* from Cancum Oris (Noma). *Am J Trop Med Hyg* 1999; 60(1): 150–6.

3. Mark KW. A history of noma, the "Face of poverty". *Plast Reconstr Surg* 2003; 111(5): 1702–7.
4. Oji C. Cancrum oris: its incidence and treatment in Enugu, Nigeria. *Br J Oral Maxillofac Surg* 2002; 40(5): 406–9.
5. Adolph HP, Yugueros P, Woods JE. Noma: a review. *Ann Plast Surg* 1996; 37(6): 657–68.
6. Enwonwu CO. Epidemiological and biochemical studies of necrotizing ulcerative gingivitis and noma (cancrum oris) in Nigerian children. *Archs Oral Biol* 1972; 17: 1357–71.
7. Enwonwu CO. Infectious oral necrosis (cancrum oris) in Nigerian children: a review. *Commun Dent Oral Epidemiol* 1985; 13: 190–4.
8. Falkler WA Jr, Enwonwu CO, Idigbe EO. Microbial understanding and mysteries of noma (cancrum oris). *Oral Dis* 1999; 5: 150–5.
9. Enwonwu CO, Falkler WA Jr, Idigbe, Afolabi BM, Ibrahim M, Onwujkwe D, Savage KO, Meeks VI. Pathogenesis of Cancrum Oris (Noma): Confounding interactions of malnutrition with infection. *Am J Trop Med Hyg.* 1999; 60(2): 223–32.
10. Paster BJ, Falkler WA Jr, Enwonwu CO, Idigbe EO, Savage KO, Levanos VA, Tamer MA, Ericson RL, Lau CN, Dewhirst FE. Prevalent bacterial species and novel phylotypes in advanced noma lesions. *J Clin Microbiol.* 2002; 40(6): 2187–91.
11. Brady-West DC, Richards L, Thame J, Moosdeen F, Nicholson A. Cancrum oris (noma) in a patient with acute lymphoblastic leukemia. A complication of chemotherapy induced neutropenia. *West Indian Med J* 1998; 47(1): 33–4.
12. Berthold P. Noma: a forgotten disease. *Dent Clin North Am* 2003; 47(3): 559–74.
13. Enwonwu CO, Falkler WA Jr, Idigbe EO, Savage KO. Noma (cancrum oris): questions and answers. *Oral Dis* 1999; 5(2): 144–9.
14. Yuca K, Yucel SA, Cankaya H, Caksen H, Calka O, Kiriş M. Report of an infant with noma (cancrum oris). *J Dermatol* 2004; 31(6): 488–91.
15. Valadas G, Leal MJ. Cancrum oris (noma) in children. *Eur J Paed Surg* 1998; 8: 47–51.
16. Sawyer DR, Nwoku AL, Rotimi VO, Hagen JC. Comparison of oral microflora between well-nourished and malnourished Nigerian children. *J Dent Child* 1986; 439–43.
17. Beisel WR. Nutrition and immune function: overview. *J Nutr* 1996; 126 (10Suppl): 2611S–5S.
18. Thurnham DI. Impact of disease on markers of micronutrient status. *Proc Nutr Society UK* 1997; 56: 421–31.
19. Enwonwu CO. Cellular and molecular effects of malnutrition and their relevance to periodontal disease. *J Clin Periodont* 1994; 21: 643–57.
20. Bengtsson AA, Rylander L, Hagmar L, Nived O, Sturfelt G. Risk factors for developing systemic lupus erythematosus: a case-control study in southern Sweden. *Rheumatology* 2002; 41(5): 563–71.
21. Mok CC, Lau CS. Pathogenesis of systemic lupus erythematosus. *J Clin Pathol* 2003; 56(7): 481–90.
22. Rahman A, Isenberg DA. Systemic lupus erythematosus. *N Engl J Med* 2008; 358(9): 929–39.
23. Gottlieb BS, Ilowite NT. Systemic lupus erythematosus in children and adolescents. *Pediatr Rev* 2006; 27(9): 323–30.
24. Loesche WJ, Syed SA, Laughton BE, Stoll J. The bacteriology of acute necrotizing ulcerative gingivitis. *J Periodontol* 1982; 53(4): 223–30.
25. Sultan SM, Ioannou Y, Isenberg DA. A review of gastrointestinal manifestations of systemic lupus erythematosus. *Rheumatology* 1999; 38: 917–32.