

U.A.8.5

DWI PRASETYO

Presentasi Poster Nasional

Pertemuan Ilmiah Tahunan Ilmu Kesehatan Anak ke -7 Ikatan Dokter Anak Indonesia

Chronic Diarrhea Due To Ulcerative Colitis: A Case Report

Surabaya **31 Oktober – 4 November 2015**

Dwi Prasetyo

SERTIFIKAT

Diberikan Kepada

DWI PRASETYO

Dalam Kegiatan Acara:


**Pertemuan Ilmiah Tahunan Ke-7
Ilmu Kesehatan Anak
Ikatan Dokter Anak Indonesia**

Surabaya, 2-4 November 2015

Sebagai:

PESERTA




Aman Bhakti Pulungan
Ketua Umum PP IDAI


Sjamsul Arief
Ketua Panitia Pelaksana



CHRONIC DIARRHEA DUE TO ULCERATIVE COLITIS : A CASE REPORT



Bonnie Arseno, Yudith Setiati Ermaya, **Dwi Prasetyo**

Departement of Child Health, Faculty of Medicine,
Universitas Padjadjaran, Dr. Hasan Sadikin General Hospital, Bandung

Background

Ulcerative colitis is a part of inflammatory bowel disease. Its clinical manifestations include diarrhea, rectal bleeding, abdominal pain, weakness, and stunted growth. Five out of 100,000 children with IBD were diagnosed at the age of less than 8 years old. Management of IBD is focused on the examinations conducted, treatment given, various types of drugs and their dosages.

Objective

To report a case of chronic diarrhea due to ulcerative colitis

Case

A girl, Z, aged 2 years and 6 months old → chronic diarrhea.

History Taking

Nausea, vomiting, abdominal bloating, low-grade fever, and decreased appetite.

Physical Examination

Severe malnutrition and dehydration

Laboratory Examination

Hb: 8.3 g/dL, CRP : 7.3 mg/L, mucus in the stool, and increased number of stool leukocytes

Treatment

- During treatment, the patient experienced hematochezia and increased bloating
- Colonoscopy showed ulcerative colitis, biopsy showed hyperplastic polyp at descending colon and rectum accompanied by non-specific inflammation
- The patient received antibiotics, anti-inflammation, antifungal, antituberculosis, and multivitamin. The patient was later discharged with improvement.

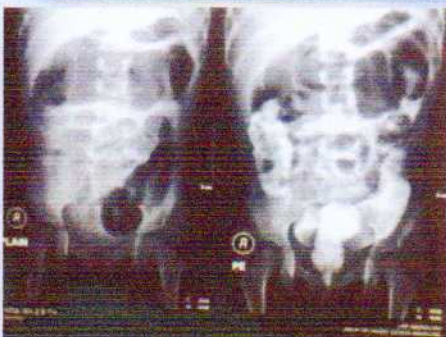


Figure 1. Colitis & Proctitis

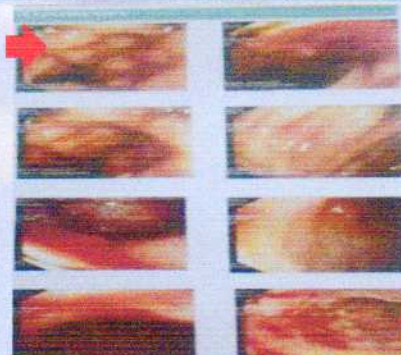

Figure 2. Ulcerative colitis

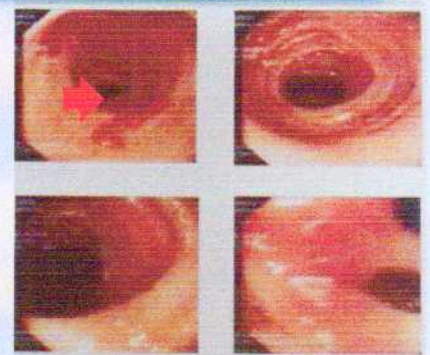


Figure 3. Ulcerative colitis
(improvement)

Conclusion

Complaint of diarrhea in children is an early symptom of a ulcerative colitis in children. Proper treatment and care, as well as investigations such as colonoscopy and biopsy can help the confirmation of diagnosis, so the patient can be spared from the worst complication.