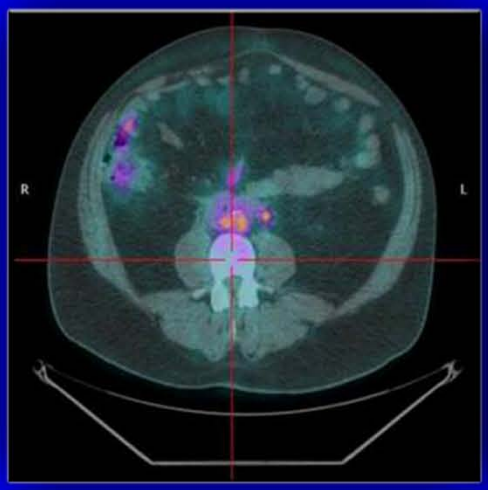

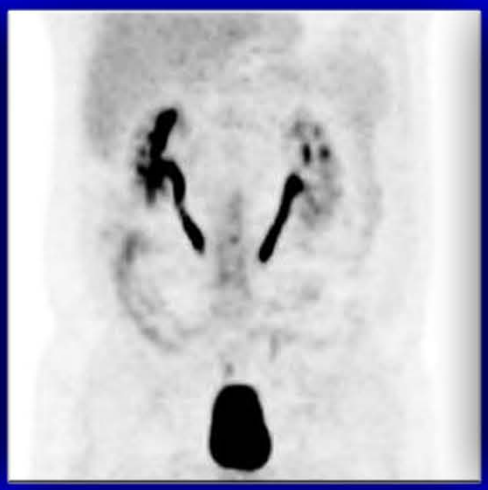

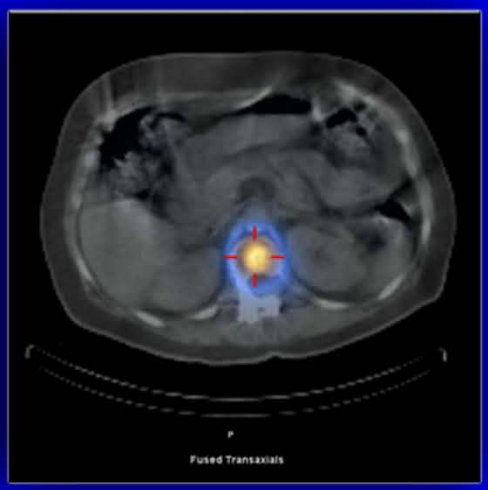

E-Learning in Nuclear Medicine

An Electronic Atlas of Interesting Nuclear Medicine Cases

IAEA

International Atomic Energy Agency

ASIAN SCHOOL OF NUCLEAR MEDICINE 2003

Asian School of Nuclear Medicine

E-Learning in Nuclear Medicine

An Electronic Atlas of
Interesting Nuclear Medicine Cases

CONTRIBUTORS

TEOFILO O.L. SAN LUIS, JR., MD
ASNM Dean
Project Leader from the Philippines

BIRENDRA DAS, MD
ASNM Vice Dean for South Asia

SOMBUT BOONYAPRAPA, MD
ASNM Vice Dean for Southeast Asia

KEIGO ENDO, MD
ASNM Country Principal for Japan

HEE-SEUNG BOM, MD
ASNM Country Principal for Korea

MOHAMED ALI ABDUL KHADER, MD
ASNM Country Principal for Malaysia

HUSSEIN KARTAMIHARDJA, MD
ASNM Country Principal for Indonesia

LUFTUN NISA, MD
ASNM Country Principal for Bangladesh

DURRE SABIH, MD
ASNM Country Principal for Pakistan

JOE RYAN A. AGGA, MD
Project Technical Operations Officer from the Philippines

KEIKO HANAMITSU
IAEA Technical Officer

FOREWORD

This Project on "E-Learning in Nuclear Medicine" was conceived as an answer to the need for continuing education of physicians, technologists and other allied professionals working in Nuclear Medicine. Wherever they are in this vast continent of Asia, these professionals have to be provided with opportunities for self-growth through every pertinent means available. As they are separated by geography, language, culture and levels of development it is obvious that these differences have impact on their health care delivery and practices.

To be sure, there have been rapid advances in Nuclear Medicine which can widen the gap even more between the more developed economies and the less developed ones. The nuclear medical infrastructure in the former can be as sophisticated and State-of-the-Art as in the Western countries while there may just be rudimentary – or even inexistent – in the latter. In whichever situation a Member State may find itself in, human resource development should still command priority attention despite difficulty in accessing nuclear technology for utilization especially in developing countries. This is compounded by scarcity of training opportunities within the Region and the relatively fewer Centers of Excellence which could serve as hubs for further education & training.

The Project seeks to foster self-directed learning addressed to physicians still in their formative years or to those who may require re-training long after formal schooling and assessments. Nuclear Medicine imaging instrumentation has come a long way from the venerable rectilinear scanner of yesteryears to the hybrid imaging devices that fuse anatomy with physiology in current usage. Newer radiopharmaceuticals, including cyclotron products, are now being used for both diagnostic & therapeutic applications. Scintigraphic images can be processed in laptops and can be transmitted across continents and discussed in teleconferences. With the wide availability of computers and PACS systems, scans and images generated by other radiological instrumentation can be viewed in different formats. Which make them good materials for e-learning.

IAEA has tasked the Asian School of Nuclear Medicine (ASNM), through RAS/0/047, to produce e-learning materials for uploading into the ANENT cyber platform. A few selected members of the ASNM Academic Senate were invited to participate in this task without leaving the confines of their homes or offices, much less their countries. This Home Assignment is a very practical means of harnessing the expertise of senior Nuclear Medicine practitioners through submission of cases which they see quite commonly in their practice, or unusual (or rare) enough to become teaching files, or something that is prevalent in their country and for which some indigenous radiopharmaceuticals can be used for imaging, or even something which can alter the management of a disease or influence its course. All clinical disciplines are represented in the array of cases, although some may have more than the others.

The format of the submitted cases is fairly uniform and user-friendly. The write-up is so concise and straight to the point, with a short history (even already the diagnosis), scintigraphic images presented with other lab data or ancillary imaging, a short discussion that delivers the message or teaching point.

Definitely not the format of a Clinico-Pathologic Conference (CPC) with a suspenseful revelation only at the end! Good enough for a quick read for the busy consultant or a harassed resident. Or to refresh memories of cases seen after all those years.

This Project is only the beginning of the effort to provide continuing education to Nuclear Medicine professionals through self-directed learning through cyber-space. It is a very modest output by the Asian School of Nuclear Medicine primarily for those with very limited means of acquiring new information. It is not intended to replace formal channels of education and training (and their corresponding assessments of terminal competencies). Who knows? Maybe when all the Member States start contributing their cases and ASNM Country Principals and Faculties and national training officers throw in their share, and with IAEA support, we might end up with a large Nuclear Medicine compendium of some sort uploaded in the ANENT cyber platform When that time comes, then, maybe, cyber space may run out of space.

TEOFILO O.L. SAN LUIS, JR., MD, MPA
Dean, Asian School of Nuclear Medicine
Editor, "E-Learning in Nuclear Medicine"

CONTENTS

1. ENDOCRINOLOGY

1.1 Lingual Thyroid (Pakistan) 2
1.2 Functional Autonomy in Multinodular Goiter (Pakistan) 5
1.3 Parathyroid Adenoma (Pakistan) 6
1.4 Parathyroid Adenoma (Bangladesh) 9
1.5 Parathyroid Adenoma (Korea) 12
1.6 Parathyroid Adenoma and Brown Tumors (Thailand) 13
1.7 Autonomous Thyroid Nodule with Papillary Thyroid Cancer (Indonesia) 18
1.8 Papillary Thyroid Cancer (Malaysia) 20
1.9 Renal Metastasis in Papillary Thyroid Cancer (Korea) 24
1.10 Cervical Lymph Node and Lung Metastases in Papillary Thyroid Cancer (Indonesia) 27
1.11 Follicular Thyroid Carcinoma (Bangladesh) 30
1.12 Follicular Thyroid Cancer with Widespread Metastases, Including the Brain (Philippines) .34
1.13 Pheochromocytoma (Korea) 41

2. MUSCULOSKELETAL SYSTEM

2.1 Avascular Necrosis due to Legg-Calve-Perthes Disease (Korea) 44
2.2 Klippel-Trenaunay Syndrome (Pakistan) 45
2.3 Polyostotic Fibrous Dysplasia (Bangladesh) 50
2.4 Idiopathic Retroperitoneal Fibrosis (Bangladesh) 52

3. GENITO-URINARY SYSTEM

3.1 Uretero-Pelvic Junction Obstruction (Pakistan) 55
3.2 Grade IV Left Vesico-Ureteral Reflux with Bacterial UTI (Indonesia) 59
3.3 Vesico-Ureteral Reflux Seen on DTPA Renal Scan (Philippines) 63
3.4 Renovascular Hypertension (Korea) 67
3.5 Horseshoe Kidney (Philippines) 69
3.6 Cake Kidney (Bangladesh) 71
3.7 Testicular Torsion (Pakistan) 75

4. GASTROINTESTINAL AND HEPATOBILIARY SYSTEM

4.1 Meckel’s Diverticulum (Bangladesh) 78
4.2 Meckel’s Diverticulum (Pakistan) 80
4.3 Meckel’s Diverticulum (Thailand) 82
4.4 Choledochal Cyst (Bangladesh) 84
4.5 Sinistro-Laterally-Rotated Gallbladder (Pakistan) 87
4.6 Congenital Biliary Artesia (Thailand) 89
4.7 Liver Hemangioma (Bangladesh) 92
4.8 Liver Hemangioma (Pakistan) 94
4.9 Left-Sided Portal Hypertension (Indonesia) 96

4.10 Large Intestine Bleeding (India) 101
4.11 Proximal Jejunal Bleeding (Korea) 106
4.12 Gastritis (Malaysia).....107

5. CARDIOLOGY
5.1 Inducible Ischemia in the Distal LAD due to Bridge (India).....110
5.2 Myocardial Ischemia – LAD Distribution (Korea) 112
5.3 RCA Thrombosis and Posterolateral MI (Thailand) 114
5.4 Acute Myocardial Infarction (Japan).....120
5.5 Takayasu's Arteritis and Arteriosclerosis of the LCA (Thailand).....122
5.6 Coronary-to-Pulmonary Steal Phenomenon (Thailand) 125

6. RESPIRATORY SYSTEM
6.1 Right-to-Left Shunt (Pakistan).....129
6.2 Right-to-Left Shunt (Philippines) 131

7. ONCOLOGY
7.1 Widespread Osseous Metastases (Philippines) 134
7.2 Prostate Cancer (Malaysia) 136
7.3 Multiple Bone Metastases from Prostate Adenocarcinoma (Thailand) 138
7.4 Lung Cancer (Japan) 141
7.5 Lung Tumor with Calcification (Indonesia) 144
7.6 Stomach Cancer (Japan) 147
7.7 Gastrinoma of the Head of the Pancreas (Thailand) 151
7.8 Hepatocellular Carcinoma (Malaysia) 155
7.9 Hepatocellular Carcinoma (Philippines) 158
7.10 Hodgkin's Lymphoma (Japan) 166
7.11 Hodgkin's Disease (Philippines) 170
7.12 Hodgkin's Lymphoma (Bangladesh) 176
7.13 Malignant Pheochromocytoma (Japan) 178
7.14 Adrenal Metastasis (Malaysia) 181
7.15 Radioiodine Uptake in Non-Lactating Mammary Gland (Bangladesh) 186
7.16 Osteosarcoma (Thailand).....188
7.17 Bone Marrow FDG Uptake (Malaysia) 193
7.18 Sarcoidosis (Japan) 195
7.19 Primitive Peripheral Neuroectodermal Tumor (Indonesia) 198
7.20 Tumor of Unknown Primary Origin (Malaysia).....201

8. INFECTION AND INFLAMMATION
8.1 Non-Specific Infection (Indonesia) 205
8.2 Whole Body Imaging to Survey for Infection (India) 208
8.3 Extrapulmonary Tuberculosis and Tuberculous Lymphadenopathy (Indonesia).....210
8.4 Peritoneal and Pulmonary Tuberculous Infection (Indonesia) 215
8.5 Tuberculous Spondylitis (Indonesia).....217
8.6 Bone Infection (Japan).....220
8.7 Complex Regional Pain Syndrome (Korea) 223

9. NEUROLOGY

9.1 Middle Cerebral Artery Occlusion (India) 226
9.2 Carotid Artery Stenosis (Japan) 228
9.3 Hemorrhagic Infarct in the Right Cerebral Hemisphere (India) 232
9.4 Depression (Japan) 234
9.5 Alzheimer Dementia (Japan) 237
9.6 Pseudoparkinsonism (India) 240
9.7 CSF Leakage at L3 Level (Korea) 242
9.8 Radiation Necrosis (Malaysia) 243
9.9 Brain Death (India) 245

10. OPHTHALMOLOGY

10.1 Right Nasolacrimal Obstruction (Malaysia) 248
10.2 Proximal Left Nasolacrimal Duct Partial Obstruction (Philippines) 250

11. PEDIATRICS

11.1 Ganglioneuroblastoma with Skeletal Metastasis (India) 254
11.2 Pulmonary Metastatic Calcification in a Child with ALL (Philippines) 256

12. MISCELLANEOUS PROCEDURES

12.1 Brown Fat (Malaysia) 260
12.2 Lymphatic Obstruction in a Lower Extremity (Korea) 262
12.3 Malignant Otitis Externa with Bony Extension (India) 263
12.4 Sjogren Syndrome (India) 265
12.5 Pleuro-Peritoneal Communication (Philippines) 267

1

ENDOCRINOLOGY

Being the first organ to be studied using radionuclide techniques, the thyroid gland has a special role to play in Nuclear Medicine applications. Both diagnostic & therapeutic components provide wealth of information toward optimum patient care. No Nuclear Medicine facility is ever complete without offering any service – either in vivo or in vitro – that is related to the thyroid. In this chapter, thyroid investigations, particularly imaging in benign or malignant conditions, remain essential and indispensible to physicians dealing with the thyroid. Radionuclide therapy with I-131 has been the cornerstone of therapeutic Nuclear Medicine, saving countless lives in the process.

Parathyroid imaging with Tc-99m sestamibi has proven very useful in localizing adenomas and in tracing its ectopic location. Nuclear Medicine's role in parathyroid studies has been instrumental particularly in clarifying obscure clinical conditions.

1.10 Cervical Lymph Node and Lung Metastases in Papillary Thyroid Cancer

(^{131}I Whole Body SPECT-CT Scan / Contributed by Indonesia)

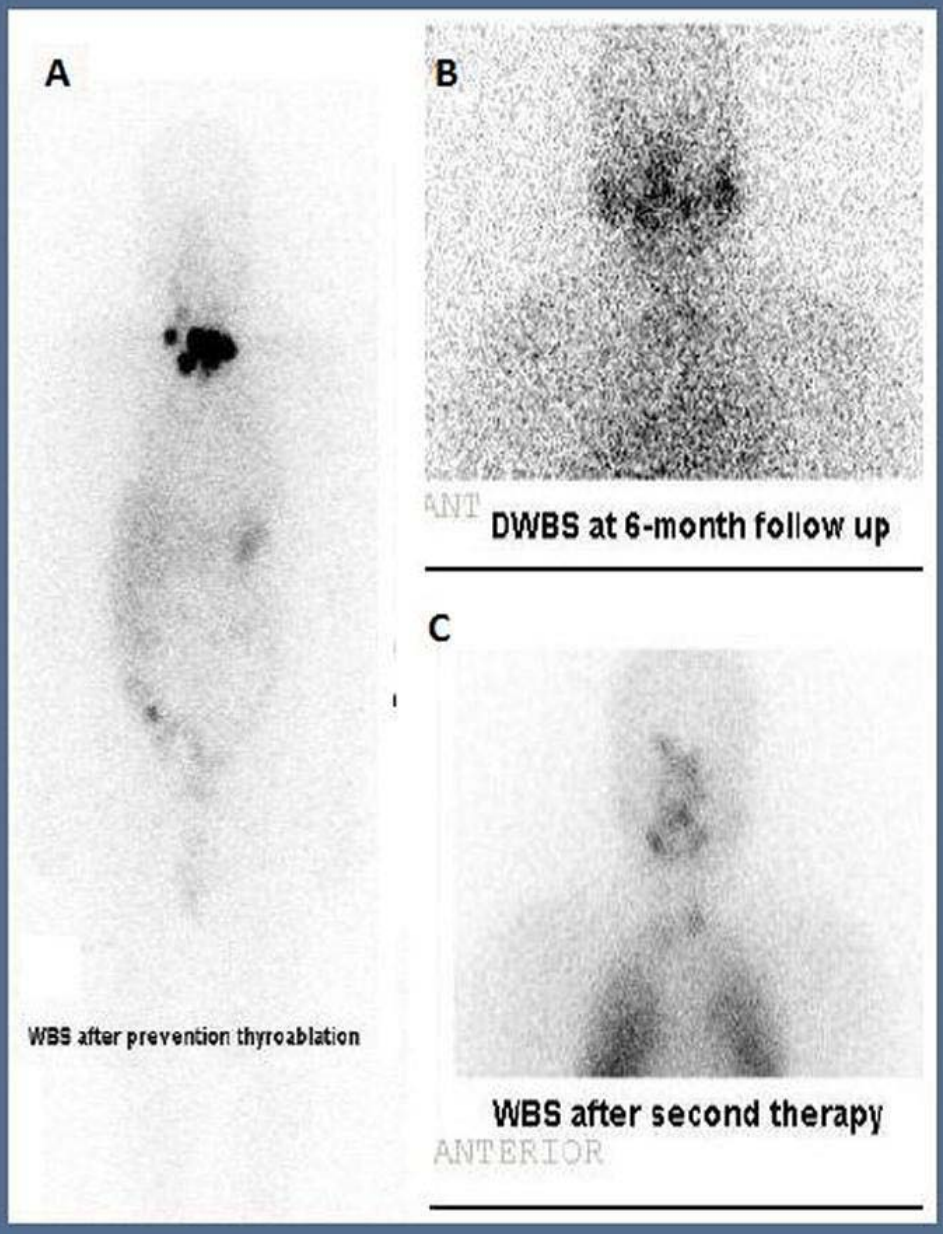

Figure 1

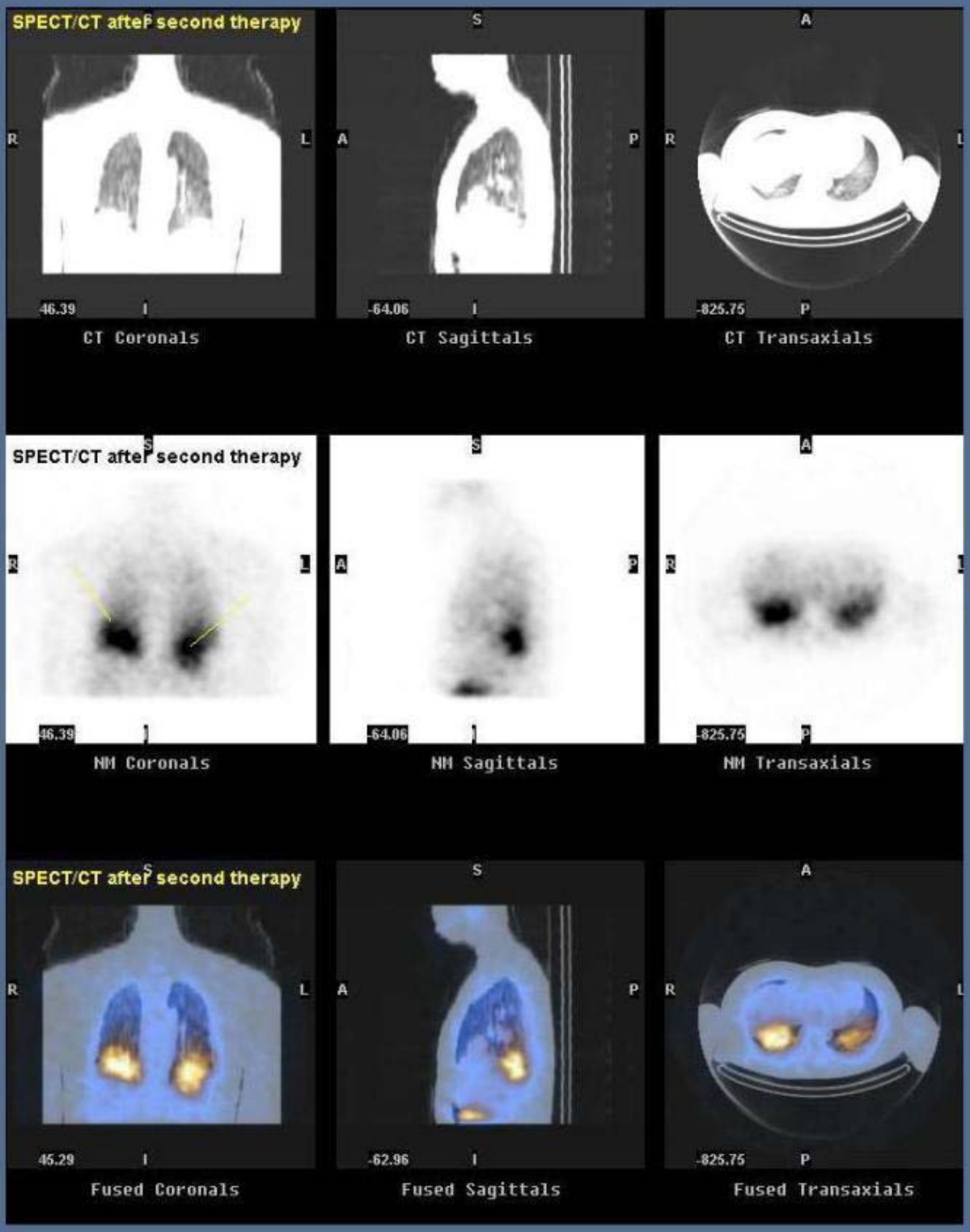
SPECT/CT after second therapy
CT Coronals
CT Sagittals
CT Transaxials
SPECT/CT after second therapy
NM Coronals
NM Sagittals
NM Transaxials
SPECT/CT after second therapy
Fused Coronals
Fused Sagittals
Fused Transaxials

Figure 2

HISTORY

A 40-year-old man with post-total-thyroidectomy and radioiodine ablation for well-differentiated thyroid cancer.

FINDINGS

Whole Body Scan. Whole Body Scintigraphy (WBS) after preventive thyroablation with sensitive thyroid stimulating hormone sensitive (sTSH) more than 60 uIU/ml showed multiple tracer uptake in thyroid bed (Figure 1A).

Follow-up Whole Body Scan, Thyroglobulin and Anti-thyroglobulin. At 6-month follow up (after withdrawal of Levothyroxine for one month), serum thyroglobulin (Tg) level was 2.49 ng/ml, negative anti-thyroglobulin antibody (ATA) and sTSH more than 161 uIU/ml. NaI-131 diagnostic whole body scintigraphy (DWBS) showed there was abnormal tracer uptake in cervical lymph node and both lungs (Figure 1B). These areas of abnormal tracer uptake were more obvious in the WBS after a second NaI-131 therapy (Figure 1C and Figure 2).

DISCUSSION

Serum Thyroglobulin (Tg) has been widely used as tumor marker for differentiated thyroid carcinoma (DTC). It is used together with WBS to detect functional thyroid tissue or metastases following total thyroidectomy and radioiodine ablation. It is assumed that if serum Tg is less than 3 ng/ml, there would be no more functional thyroid tissue or metastasis left, so further radioiodine therapy is not needed. However in some circumstances, there is a discrepancy between these two parameters. In this case, serum level of Tg was less than 3ng/ml, but WBS was positive. This discrepancy may be due to (1) presence of foci of thyroid tissue in isolated lymph node metastasis; (2) abnormal form of Tg which cannot be recognized by monoclonal antibody in the assay.

PEARLS

It is recommended to do diagnostic I-131 WBS, when serum Tg <3ng/ml in the follow-up of patients with DTC, particularly if the remaining normal thyroid tissue is quite big, with or without suspected metastases seen in post-radioablation scan.